

The Right Axillary Incision: A Potential New Standard of Care for Selected Congenital Heart Surgery

Timothy Lee, BS,* Aaron J. Weiss, MD,* Elbert E. Williams, MD,* Fuad Kiblawi, MD,[†] Joanna Dong, BA,* and Khanh H. Nguyen, MD*

Although the median sternotomy has been the traditional approach for congenital heart surgery, young patients and their families often find the midline scar to be cosmetically unappealing. At our center, a right transverse axillary incision has become the standard approach for many congenital cardiac lesions because of its safety, versatility, and unsurpassed aesthetic result. We present our experience with the axillary approach for a diverse array of congenital defects. A retrospective review of patients receiving a right transverse axillary incision for congenital cardiac surgery between 2005 and 2016 was conducted. The right transverse axillary incision was performed in 358 patients for 24 unique procedures. Median age was 5 years (range 1 month–60 years) and 225 patients (63%) were female. Median weight was 17 kg (range 4–124 kg), with 19 patients (5%) weighing less than 6 kg. The most common lesions were atrial septal defects (n = 244, 68%) and ventricular septal defects (n = 72, 20%). As experience with this approach increased, other repairs included subvalvular aortic membrane resection (n = 10, 3%), tetralogy of Fallot repair (n = 7, 2%), ventricular assist device placement (n = 3, 1%), and mitral valve repair (n = 2, 1%). There were no intraoperative deaths or conversions to sternotomy. In-hospital complications included mortality (n = 1, 0.3%), reoperations for bleeding (n = 5, 1%), pneumothorax or pleural effusion (n = 6, 2%), and permanent pacemaker (n = 4, 1%). The right axillary incision allows a safe and effective repair for a broad range of congenital heart defects and is a potential new standard of care for many patients.

Semin Thoracic Surg ■■■:■■■–■■■ © 2018 Published by Elsevier Inc.

Keywords: congenital heart surgery, cardiac surgery, pediatric heart surgery, minimally invasive, incision

*Department of Pediatric and Congenital Cardiac Surgery, Maria Fareri Children's Hospital, Westchester Medical Center, Valhalla, New York

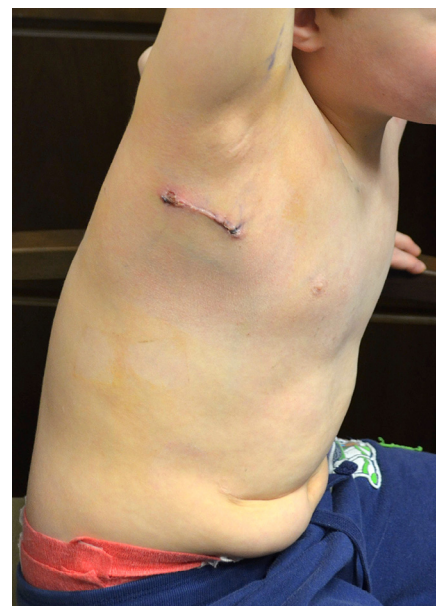[†]Department of Pediatric and Congenital Cardiac Surgery, Maria Fareri Children's Hospital, Westchester Medical Center, 100 Woods Road, Valhalla, NY 10595

Conflicts of interest and sources of funding: There was no funding for this research. The authors have no conflicts of interest to disclose.

Presented at the Western Thoracic Surgery Association 43rd Annual Meeting, 2017.

This study was approved by the data protection review board of the New York State Department of Health and the Program for Protection of Human Subjects at the Icahn School of Medicine at Mount Sinai GCO #11-1081(0001) on January 25, 2016, and GCO #15-2265(0001) on March 13, 2017.

Timothy Lee is responsible for study concept and design, data acquisition, analysis and interpretation, statistical analysis, drafting, and critical revision of manuscript. Aaron J. Weiss and Khanh H. Nguyen are responsible for study concept and design, data acquisition, analysis and interpretation, drafting, and critical revision of manuscript. Elbert E. Wil-



A 10-year-old patient 1 week postoperatively after a right axillary incision.

Central Message

The right axillary incision can be performed safely to repair a diverse set of congenital cardiac lesions and provides a potential new standard of care for selected congenital cardiac patients.

Perspective Statement

The scar left by a median sternotomy is often a source of apprehension for congenital cardiac surgery patients and their families. To overcome this, the right transverse axillary incision is a valuable surgical approach for a wide variety of congenital cardiac surgeries that allows for excellent results and an unsurpassed cosmetic outcome.

liams, Fuad Kiblawi, and Joanna Dong are responsible for data acquisition, analysis and interpretation, drafting, and critical revision of manuscript.

Address reprint requests to Khanh H. Nguyen, MD, Department of Cardiovascular Surgery, Mount Sinai Medical Center, 1190 Fifth Ave, Guggenheim Pavilion, 2 W, New York, NY 10029. E-mail: Khanh.Nguyen@wmchealth.org

INTRODUCTION

The median sternotomy has been the conventional approach for congenital cardiac surgeries, as it provides excellent access to the heart and great vessels. However, the residual scar may prove cosmetically unappealing, with potential psychological detriment to young children, particularly prepubescent females.¹ Recently, Yan et al demonstrated that approximately 35% of patients and their families found the aesthetic result of a median sternotomy to be unsatisfactory in the immediate postoperative period.² Previously, Bleiziffer et al reported that more than a decade postoperatively up to 27% of median sternotomy patients reported “impaired self-confidence through scarring.”³ Many alternative surgical incisions have been utilized, yet each has its own limitations. For example, a partial sternotomy still leaves behind a central residual scar⁴; the anterior thoracotomy has been shown to cause asymmetric breast and pectoral muscle development on long-term follow-up³; and the posterior thoracotomy provides suboptimal exposure and potential for scoliosis.¹

To alleviate the cosmetic concerns of patients, we have adopted the right transverse axillary incision as our primary approach for surgical correction of a wide variety of congenital cardiac malformations. This incision provides an unsurpassed cosmetic and functional result, as the scar remains hidden high in the axilla, and incision of the back and anterior chest is avoided. Previously we reported our use of this incision for a limited number of procedures.⁵ As our experience with this approach has grown, and with continued refinement of protocols and instruments, we now utilize the right axillary incision as our standard of care for a broad range of congenital defects. Here, we report our experience with the right transverse axillary incision for congenital cardiac surgery and demonstrate that its routine use provides a safe and cosmetically appealing outcome for a wide variety of malformations.

METHODS

Study Protocol

A retrospective institutional chart review was performed for consecutive patients undergoing a right transverse axillary incision for congenital cardiac surgery between September 1, 2005, and September 1, 2016, by a single congenital heart surgeon (KHN). Surgeries were performed at 2 institutions—The Mount Sinai Hospital (New York City, NY) and St. Joseph’s Hospital (Paterson, NJ). We did not exclude any patients from this report. Baseline patient demographic and clinical characteristics were obtained from the electronic medical record and included all relevant preoperative, intraoperative, and postoperative variables. Postdischarge follow-up was completed by chart review of subsequent inpatient admissions, outpatient records, and echocardiographic reports. This study was approved by the Program for the Protection of Human Subjects Institutional Review Board at the Icahn School of Medicine at Mount Sinai. The approval included a waiver of informed consent and permitted retrospective review of patient data because of minimal risk.

Study Outcomes

The primary study outcome was intraoperative all-cause mortality. Secondary outcomes included intraoperative conversion to median sternotomy, reoperations for bleeding, pneumothorax or pleural effusion requiring procedural intervention, hemidiaphragm paralysis identified by echocardiogram, conduction abnormality requiring permanent pacemaker implantation, residual intracardiac defect requiring reoperation, and new or residual intracardiac defects identified by echocardiogram. Additionally, we identified postdischarge rates of readmission for surgical complications, reoperation or reintervention, and new or residual defects identified by echocardiogram. For the outcome of pneumothorax or pleural effusion, intervention was defined as a chest tube, thoracentesis, or pigtail catheter. A new intracardiac defect was defined as a lesion of moderate severity or greater postoperatively at a location where no defect existed on preoperative echocardiogram. A residual intracardiac defect was defined as a lesion that was attempted to be repaired during the index procedure, but that was assessed by postoperative echocardiography as having a defect of moderate severity or greater. Reintervention for residual intracardiac defects was defined as a cardiac surgery, percutaneous intervention including, but not limited to, device closures and transcatheter valves. Readmission for a surgical complication was defined as a hospital readmission occurring within 30 days postoperatively if the primary diagnosis of the readmission was one of the perioperative outcomes listed previously.

Surgical Technique

The procedure is undertaken with general endotracheal anesthesia. Central venous access is performed either through large peripheral intravenous lines or a central line, and an arterial line is placed. Foley catheterization is routinely performed. A spinal block is performed with morphine to minimize the intravenous opiate requirements administered intra- and postoperatively. A transesophageal echocardiography probe is placed for routine intraoperative imaging. The patient is then positioned in the left lateral decubitus, with the right arm abducted over the head to optimize the opening of the right axillary intercostal spaces. A transverse incision line, ranging from 3.5 to 7 cm in length depending on patient size, is marked on the patient’s skin at the level of the fourth intercostal space between the anterior and the posterior axillary lines (Fig. 1A). The patient is prepped and draped in sterile fashion, and the skin incision is made through the line which was previously marked, sparing the latissimus dorsi posteriorly and serratus anterior anteriorly. Although not necessary, the right lung can be isolated using single lung ventilation, particularly in small babies. If single lung ventilation is not possible, the lungs are deflated before opening the pleura to avoid lung parenchymal injury. Upon entering the pleural space, various sized retractors can be placed that are appropriate for the specific size of the patient, and the right lung was retracted posteriorly. The thoracic cavity is insufflated with CO₂ to prevent air embolism.

After removing the right lobe of the thymus, the pericardium is opened anterior to the phrenic nerve, with care taken to avoid phrenic nerve injury. Pericardial stay sutures are placed to opti-

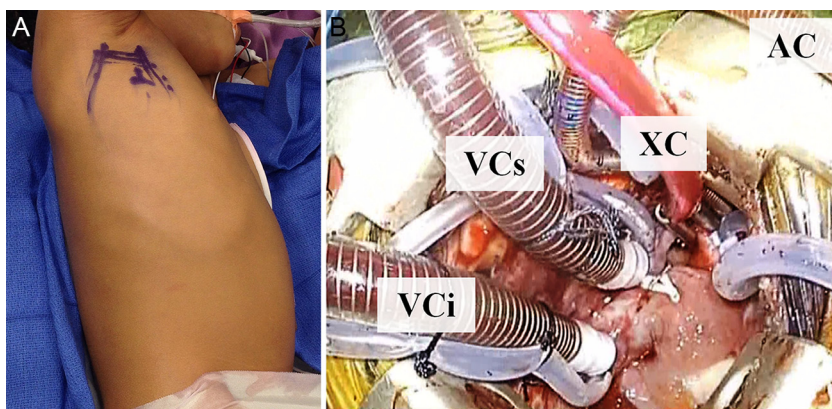

Figure 1. The right transverse axillary incision in a 5-year-old patient undergoing a subarterial ventricular septal defect repair. (A) Before the start of surgery, the incision line is marked between the anterior and the posterior axillary lines in the fourth intercostal space. (B) Surgeon’s view after application of the cross-clamp (XC), demonstrating the central cannulation setup including direct aortic cannulation (AC), as well as bicaval cannulation with venous cannulae in the superior vena cava (VCs) and inferior vena cava (VCi). (Color version of figure is available online.)

mize exposure and aid in isolating the lung from the operative field. The patient is then heparinized with a dosage of 70-80 units/kg. Aortic and bicaval cannulation are performed centrally in a routine fashion (Fig. 1B). After commencing cardiopulmonary bypass, simple procedures such as an atrial septal defect (ASD) repair are routinely completed on a fibrillated heart utilizing ventricular pacing wires. For more complex procedures, the aorta is cross-clamped and cardioplegic arrest is undertaken using blood cardioplegia. Next, surgical repair of the congenital heart defect is performed, with the aid of a customized tray of retractors and endoscopic tools (Fig. 2) to optimize exposure and maneuver within the small space. At the conclusion of the intracardiac repair, the cross-clamp is removed and modified ultrafiltration is commenced before decannulation.

The heart is evaluated by transesophageal echocardiography by our team of pediatric cardiac anesthesiologists to confirm the absence of residual or new defects and to aid in deairing. Intercostal nerve block with bupivacaine is routinely performed before completion of the procedure, infiltrating ribs 3-5. A single chest tube and, if needed, pacing wires are placed through the initial incision. The skin is closed, with the residual scar between the anterior and the posterior axillary lines (Fig. 3). Patients are routinely extubated in

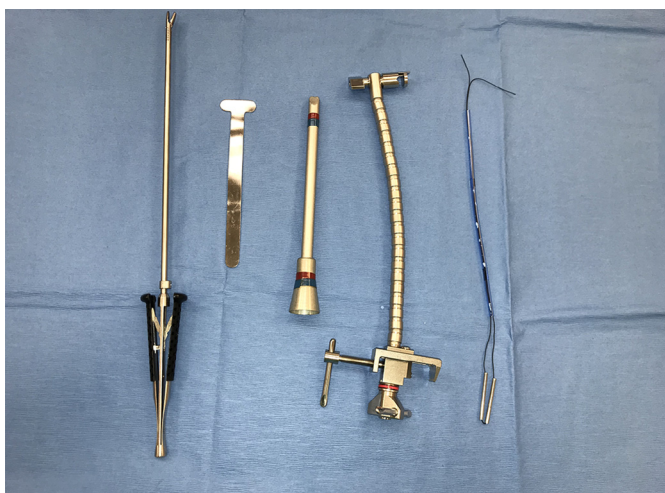

Figure 2. Specialized instruments developed to perform surgery through the right transverse axillary incision. Left to right: endoscopic needle holder, modified lung retractor, knot pusher, self-retaining retractor, and aortic cross-clamp. (Color version of figure is available online.)

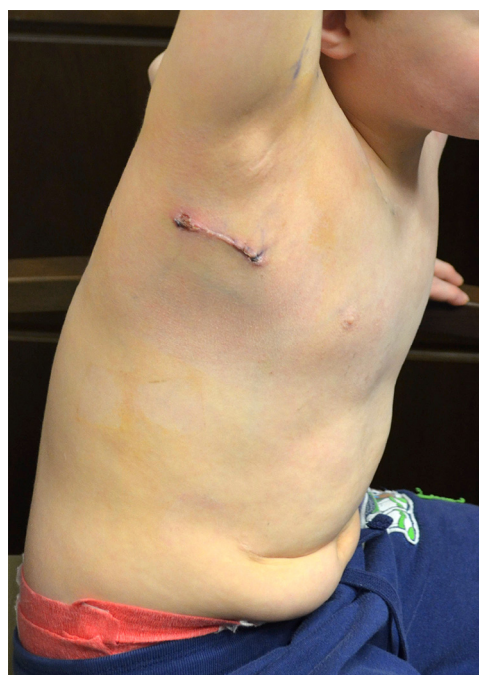

Figure 3. A 10-year-old congenital heart surgery patient 1 week postoperatively, with arm abducted to expose a healing right transverse axillary incision. (Color version of figure is available online.)

CONGENITAL – THE RIGHT AXILLARY INCISION

the operating room if they are hemodynamically stable with minimal inotropic support, normothermic, and have satisfactory arterial blood gases on minimal ventilator settings.

Data Analysis

Data are presented as actual counts with percentages. Continuous values were non-normally distributed and presented as median and interquartile ranges. All statistical analyses were performed using SAS version 9.4 (SAS Institute Inc, Cary, NC).

RESULTS

Between September 2005 and September 2016, the right axillary incision was performed in 358 patients (Table 1). Operations were performed at The Mount Sinai Hospital for 285 patients (80%) and St. Joseph's Hospital for 73 patients (20%). Median patient age was 5 years (range 1 month-60 years). Median weight was 17 kg (range 4-124 kg), with 152 patients (42%) weighing less than 15 kg and 19 patients (5%) weighing less than 6 kg. Two hundred and twenty-five patients (63%) were female.

The right transverse axillary incision was utilized for 24 unique primary procedures. A full list of primary procedures is provided in Table 1. The most common procedures were ASD repairs

(n = 244, 68%) and ventricular septal defect (VSD) repairs (n = 72, 20%). Additional procedures included subvalvular aortic membrane resection (n = 10, 3%), tetralogy of Fallot repair (n = 7, 2%), ventricular assist device placement (n = 3, 1%), mitral valve repair (n = 2, 1%), extracardiac Fontan (n = 1, 0.3%), and atrioventricular septal defect repair (n = 1, 0.3%).

Sixty-seven patients (19%) underwent concomitant repair of at least 2 lesions. The most common combined procedures were VSD patch repair plus patent foramen ovale closure (n = 9, 3%), ASD patch repair plus mitral valve cleft closure (n = 8, 2%), and sinus venosus/partial anomalous pulmonary venous drainage patch repair plus patent foramen ovale closure (n = 8, 2%). Additionally, 18 patients (5%) had 3 or more lesions repaired concomitantly, including 6 patients with a tetralogy of Fallot repair, 6 patients with a primary VSD repair, and 5 patients with a primary ASD repair.

A total of 25 patients (7%) had a previous cardiac intervention or surgery (Table 2), including attempted percutaneous ASD closure device (n = 13, 4%), balloon pulmonary valvuloplasty (n = 3, 1%), patent ductus arteriosus ligation (n = 2, 0.6%), bidirectional Glenn (n = 1, 0.3%), coarctation repair (n = 2, 0.6%), atrial septostomy (n = 1, 0.3%), patent ductus arteriosus stent (n = 1, 0.3%), pericardial drainage (n = 1, 0.3%), and prior VSD patch (n = 1, 0.3%).

Table 1. Primary Procedures of 358 Patients Who Received Congenital Heart Surgery Through a Right Axillary Incision, From Most to Least Frequent Procedure

Primary Procedure	Number of Patients, Total (Female)	Median (Interquartile Range)				
		Age (y)	Weight (kg)	Surgery Time (min)	CPB Time (min)	Length of Stay (d)
ASD repair, primary	157 (103)	5 (2-11)	17 (12-37)	120 (112-162)	12 (8-26)	3 (2-3)
ASD repair, patch	54 (33)	5 (3-10)	18 (12-32)	179 (157-217)	50 (38-84)	3 (2-4)
VSD repair, patch	54 (30)	1 (0.6-5)	8 (6-16)	206 (182-237)	90 (78-112)	3 (3-5)
ASD sinus venosus/PAPVR, patch repair	33 (20)	7 (4-19)	27 (15-61)	225 (194-277)	82 (68-104)	3 (3-4)
VSD repair, primary	18 (11)	5 (4-10)	19 (17-32)	181 (163-224)	86 (72-96)	3 (2-3)
Subvalvular aortic membrane resection	10 (8)	7 (2-9)	29 (14-47)	175 (161-206)	66 (55-78)	3 (3-3)
Tetralogy of Fallot repair	7 (3)	0.3 (0.2-0.4)	6 (5-7)	292 (226-324)	144 (93-163)	6 (4-11)
DCRV resection + RVOT patch	4 (3)	9 (4-14)	25 (14-52)	208 (156-263)	54 (48-79)	3 (3-4)
LVAD implantation	3 (1)	2 (0.2-7)	18 (9-24)	162 (114-287)	–	15 (13-19)
Atrial septation	2 (1)	11 (0-21)	64 (4-124)	281 (235-327)	114 (99-129)	11 (2-20)
Mitral valve repair	2 (2)	12 (1-22)	29 (7-51)	223 (198-248)	131 (123-139)	5 (4-6)
Warden procedure	2 (1)	25 (1-49)	40 (12-67)	151 (38-263)	198 (136-259)	5 (3-7)
Atrial myxoma resection, left	1 (1)	15	62	209	75	7
Atrioventricular septal defect repair	1 (1)	0.3	6	433	266	6
Cortriatrium resection	1 (0)	11	42	185	42	2
Fontan extra-cardiac	1 (0)	3	11	296	131	44
PAPV reimplantation to left atrium	1 (0)	34	68	355	154	5
Pericardial window	1 (1)	1	8	37	–	5
RVOT transannular patch	1 (0)	0.6	7	184	75	6
Removal of ASD closure device	1 (1)	39	66	214	67	4
Scimitar syndrome repair	1 (1)	11	34	273	120	3
Tricuspid valve repair	1 (1)	5	21	285	386	18
Tricuspid valve vegetation removal	1 (1)	26	51	254	123	5
Vascular ring division	1 (0)	18	59	41	–	2

CPB, cardiopulmonary bypass; DCRV, double chambered right ventricle; LVAD, left ventricular assist device; PAPV, partial anomalous pulmonary vein; PAPVR, partial anomalous pulmonary venous return; RVOT, right ventricular outflow tract.

Table 2. Procedures of 25 Patients With a Previous Cardiac Intervention or Surgery, Before the Index Surgery Performed Through a Right Axillary Incision

Index Surgery	Previous Cardiac Intervention/Surgery	Number of Patients
ASD closure	Percutaneous ASD closure device	13
ASD closure	PDA closure	2
ASD closure	Balloon pulmonary valvuloplasty	1
Warden procedure	Balloon pulmonary valvuloplasty	1
Tricuspid valve repair	Balloon pulmonary valvuloplasty	1
LVAD placement	Atrial septostomy	1
Extracardiac Fontan	Bidirectional Glenn	1
VSD closure	Coarctation resection and end-to-end anastomosis	1
Subaortic resection	Coarctation repair	1
Tetralogy of Fallot repair	PDA stent	1
Pericardial window	Pericardial drain	1
Subaortic resection	VSD patch	1

LVAD, left ventricular assist device; PDA, patent ductus arteriosus.

Cardiopulmonary bypass was performed for 353 patients (99%), with a median time of 49 minutes (range 5-386 minutes); cardiopulmonary bypass was not utilized for left ventricular assist device placement (n = 3, 1%), pericardial window (n = 1, 0.3%), or vascular ring division (n = 1, 0.3%). Median surgery time was 174 minutes (range 37-433 minutes).

There were no intraoperative deaths or conversions to sternotomy. Successful extubation in the operating room occurred in 342 patients (96%), with 6 patients (2%) requiring reintubation postoperatively. The median postoperative length of stay was 3 days (range 2-44 days), with 254 patients (71%) discharged within 3 days. Postoperative surgical complications included 1 mortality (0.3%), 5 patients (1%) requiring reoperation for bleeding, 6 patients (2%) with right-sided pneumothorax or pleural effusion requiring surgical intervention, 4 patients (1%) requiring permanent pacemaker, and 3 patients (1%) with asymptomatic right hemidiaphragm paralysis. The single postoperative death occurred in a patient with acute fulminant myocarditis and preoperative multiorgan failure requiring emergent left ventricular assist device placement.

After discharge, the median follow-up was 62 days (range 0 day-10.2 years). Follow-up extended beyond the index admission in 305 patients (85%), beyond 30 days in 196 patients (55%), and beyond 1 year in 129 patients (36%). In total, 8 patients (2%) were readmitted within 30 days of the initial surgery for complications including pleural effusion (n = 2, 1%), pneumothorax (n = 2, 1%), right atrial thrombus (n = 1, 0.3%), atrioventricular block (n = 1, 0.3%), junctional ectopic tachycardia (n = 1, 0.3%), and chest pain with a negative workup (n = 1, 0.3%). Three patients (1%) needed an additional surgery or intervention: 1 patient an initial transitional atrioventricular canal repair, VSD patch closure, and ASD primary closure who developed a residual ASD lesion treated with percutaneous closure device 1 year after the index procedure; and 2 patients who required re-repair of the mitral valve through a median sternotomy after an initial combined mitral valve cleft closure and ASD patch repair.

Echocardiographic follow-up after the patients were discharged was available for 263 patients (73%), beyond 30 days in 163 patients (46%), and beyond 1 year in 115 patients (32%). At the time of the most recent echocardiogram, moderate or severe residual defects were found in 3 patients (1%). Additionally, new defects were discovered in 2 patients (1%), both of whom developed moderate tricuspid regurgitation after initial isolated ASD repairs.

DISCUSSION

The goal of congenital cardiac surgery is to safely and durably repair all defects, while providing patients with improved quality of life and maximizing their life expectancy. For patients with defects that may be reliably repaired with excellent outcomes, surgeons have the opportunity to provide further benefit by reducing the iatrogenic effects of surgery. Common methods to reduce surgical effects include decreasing bypass time, early extubation in the operating room, fast-tracking patients when safe, and utilizing incisions which minimize residual scarring. Anecdotally, we find that improved cosmesis, achievable with incisions avoiding a midline scar, is the most frequent request of our patients.

Since 2005, the approach of choice at our center has been the right transverse axillary incision as it avoids the large, central scar from a midline sternotomy. In our experience, complete sparing of muscle and preserving the sternum integrity allow patients to return to normal activities faster (in our experience, reported by patients to be within 4 weeks) than after a sternotomy (which often requires more than a month of inactivity). In contrast to the posterior thoracotomy, the right transverse axillary incision avoids the latissimus muscles posteriorly, thereby decreasing postoperative pain⁶ and avoiding potential growth deformities such as scoliosis. In contrast to the anterolateral thoracotomy, the transverse axillary thoracotomy preserves the mammary gland and breast tissue, thereby allowing normal breast development. We believe the cosmetic result to be superior to all other approaches, as the remaining scar is peripherally located and hidden from plain view with the

CONGENITAL – THE RIGHT AXILLARY INCISION

arm abducted. Finally, we have found this approach to be versatile, allowing safe and effective surgeries to repair many different congenital defects.

The right transverse axillary approach was originally described for congenital cardiac surgery by Schreiber et al from Munich in 2003.⁷ Initially, the approach was performed only for ASD repairs in patients aged 4-12 years. Since then, several centers have reported use of the right axillary incision with an expanded number of indications.^{1,8,9} We previously published our initial experience with the right transverse axillary incision,⁵ primarily for correction of ASDs. At that time, we found similar intraoperative and in-hospital outcomes with the right axillary incision and the mini-sternotomy to repair ASD ostium secundum lesions; other centers have also reported similar results comparing sternotomy and axillary incisions for simple defects.^{2,9}

Our preference for this incision has grown considerably since that last report, such that we have felt safe using this approach for an increasing number of procedures. To date, we have used this technique for 24 unique individual procedures. We are happy to report excellent outcomes in our patients, with no intraoperative deaths, no requirements for conversion to sternotomy, few morbidity complications, few patients with residual defects on immediate and available long-term follow-up, and excellent cosmesis for patients we have seen in the office. The versatility of this incision is evidenced by the breadth of repairs, as well as concomitant repair of 2 or more lesions in 85 patients (24%). We are aware of only 3 patients who required reoperation or reintervention, 2 of whom were young mitral valve patients (a patient population with notoriously high rates of reoperation after congenital repair).¹⁰ Additionally, only 2 patients displayed new defects postoperatively, with both patients developing moderate tricuspid regurgitation in the immediate postoperative period after ASD repairs. We hypothesize that this was likely due to the excessive left-to-right shunting and right heart remodeling commonly observed in ASDs.¹¹

Our axillary incision technique differs in a few key ways from the methods utilized at other centers. First, cannulation is entirely central, whereas other centers prefer femoral access.¹ Central cannulation permits the use of this approach in smaller sized babies (for whom femoral cannulation is typically avoided) and thus precludes the need to wait until babies are large enough to receive peripheral cannulation. Nearly half of the patients in our series weighed less than 15 kg, whereas other centers require patients to weigh ≥ 15 kg to facilitate peripheral cannulation,¹² and 5% of our patients weighed even less than 6 kg. In fact, we find younger patients to be more amenable to the right transverse axillary approach because the chest is smaller, the heart is closer in distance to the incision, and there is less subaxillary fat than with teenagers and adults. This cohort additionally included heavier and older patients, as the maximum patient size was 124 kg and the maximum patient age was 60 years. To allow this technique for small and large patients, we have compiled a unique set of tools that are sometimes helpful for surgical repair (Fig. 2). Our technique further differs from other centers in that our incision is transverse, compared with a number of centers which prefer vertical incisions

crossing Langer's lines.^{9,13} This vertical right axillary incision is primarily utilized by Chinese centers, and similar to transverse axillary centers the vertical incision is primarily utilized to repair ASDs and VSDs.^{2,9,13,14} Finally, a chest tube placed through the initial right axillary incision minimizes the number of incisions and leaves the anterior chest and abdomen unscathed. Importantly, we believe the right axillary incision requires a distinct skill set from port access surgery with or without robotic assistance. Although both are minimally invasive techniques, port access surgery requires an entirely unique set of instruments, peripheral cannulation, and video assistance, among other important differences.

Although the right transverse axillary incision is our preferred surgical approach, we do note that this approach has limitations. The lack of familiarity with viewing the cardiac anatomy from this vantage point may prove difficult for surgeons without experience using this incision. Depending on the patient age, size, and type of defect, the small lateral incision may result in less exposure than with a full median sternotomy, and thus some repairs may be more difficult. We do not believe this incision is suitable for certain malformations, such as single ventricle anatomy or hypoplastic aortic arch requiring arch reconstruction. Furthermore, because of the intentionally small size of the incision, care must be taken to prevent the field from becoming crowded with cannulas and thus causing obstruction of the surgeon's view. We have developed unique tools to aid in access and exposure, which aid greatly in conduction of the surgery (Fig. 2). However, often times it is the primary surgeon who performs the majority of the operation and this limits a trainee's ability to actively observe. The small incision may also contribute to longer bypass times reported in this study, and longer bypass times may place the patient at increased risk of morbidity such as postoperative coagulopathy.

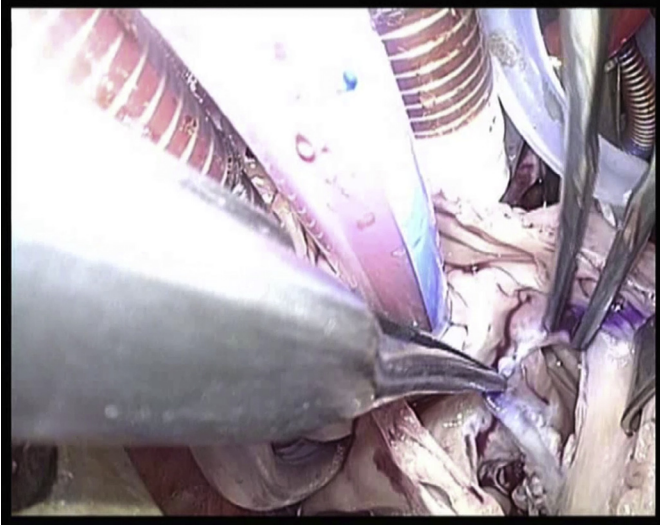
This study has several limitations. As our patient cohort is from a wide referral base, often the postdischarge follow-up and imaging did not occur at the site of the index procedure, with patients likely returning to their referring cardiologists for follow-up. The result is a potential underestimation of the rate of new or residual lesions postoperatively, although we remain encouraged by the outcomes of patients for whom these data are available. Second, despite our best attempts, we were unable to find a suitable control group to truly validate the safety and efficacy of our approach for more complex lesions. Finally, we have not collected data on long-term patient satisfaction with this incision or any other incisions. This is a potential focus of a future study, as this information would help validate the right axillary incision as a cosmetically superior incision.

CONCLUSIONS

With a refined approach and increased experience, the right axillary incision has become a safe and effective alternative to the median sternotomy for a diverse array of congenital cardiac defects. This approach may serve as a potential new standard of care for many congenital cardiac patients.

SUPPLEMENTARY MATERIAL

The following is the supplementary data to this article:



Video S1. Repair of Tetralogy of Fallot performed in a 3-month-old boy utilizing a right axillary incision.

REFERENCES

1. Pretre R, Kadner A, Dave H, et al: Right axillary incision: A cosmetically superior approach to repair a wide range of congenital cardiac defects. *J Thorac Cardiovasc Surg* 130:277-281, 2005
2. Yan L, Zhou ZC, Li HP, et al: Right vertical infra-axillary mini-incision for repair of simple congenital heart defects: A matched-pair analysis. *Eur J Cardiothorac Surg* 43:136-141, 2013
3. Bleiziffer S, Schreiber C, Burgkart R, et al: The influence of right antero-lateral thoracotomy in prepubescent female patients on late breast development and on the incidence of scoliosis. *J Thorac Cardiovasc Surg* 127:1474-1480, 2004
4. Nicholson IA, Bichell DP, Bacha EA, et al: Minimal sternotomy approach for congenital heart operations. *Ann Thorac Surg* 71:469-472, 2001
5. Nguyen K, Chin C, Lee DS, et al: The axillary incision: a cosmetic approach in congenital cardiac surgery. *J Thorac Cardiovasc Surg* 134:1358-1360, 2007
6. Benedetti F, Vighetti S, Ricco C, et al: Neurophysiologic assessment of nerve impairment in posterolateral and muscle-sparing thoracotomy. *J Thorac Cardiovasc Surg* 115:841-847, 1998
7. Schreiber C, Bleiziffer S, Lange R: Midaxillary lateral thoracotomy for closure of atrial septal defects in pre-pubescent female children: Reappraisal of an "old technique". *Cardiol Young* 13:565-567, 2003
8. Dave HH, Comber M, Solinger T, et al: Mid-term results of right axillary incision for the repair of a wide range of congenital cardiac defects. *Eur J Cardiothorac Surg* 35:864-870, 2009
9. Da Silva LF, da Silva JP, Turquetto ALR, et al: Horizontal right axillary minithoracotomy: Aesthetic and effective option for atrial and ventricular septal defect repairs in infants and toddlers. *Rev Bras Cir Cardiovasc* 29:123-130, 2014
10. Oppido G, Davies B, McMullan DM, et al: Surgical treatment of congenital mitral valve disease: Midterm results of a repair-oriented policy. *J Thorac Cardiovasc Surg* 135:1320-1321, 2008
11. Fang F, Wang J, Zip GW, et al: Predictors of mid-term functional tricuspid regurgitation after device closure of atrial septal defect in adults: Impact of pre-operative tricuspid valve remodeling. *Int J Cardiol* 187:447-452, 2015
12. Schreiber C, Bleiziffer S, Kostolny M, et al: Minimally invasive midaxillary muscle sparing thoracotomy for atrial septal defect closure in prepubescent patients. *Ann Thorac Surg* 80:673-676, 2005
13. Yang X, Wang D, Wu Q: Repair of atrial septal defect through a minimal right vertical infra-axillary thoracotomy in a beating heart. *Ann Thorac Surg* 71:2053-2054, 2001
14. Hu CH, Tan J, Chen S, et al: Comparison of clinical outcomes and post-operative recovery between two open heart surgeries: Minimally invasive right subaxillary vertical thoracotomy and traditional median sternotomy. *Asian Pac J Trop Med* 7:625-629, 2014